

ANALYSIS

Ethical dilemmas in the acute setting: a framework for clinicians

Nearly all healthcare professionals will encounter ethical dilemmas in their work but rarely get any training in how to resolve them. Using a real case, **Daniel Sokol and colleagues** illustrate a structured approach to ethical analysis

Daniel K Sokol *honorary senior lecturer in medical ethics and barrister*¹, William A McFadzean *consultant anaesthetist*², William A Dickson *director*³, Iain S Whitaker *honorary professor of plastic, reconstructive, and aesthetic surgery*³

¹Department of Primary Care and Public Health, Charing Cross Campus, Imperial College London, London W6 8RF, UK; ²Morrison Hospital, Swansea SA6 6NL, UK; ³Welsh Centre for Burns and Plastic Surgery, Morrison Hospital

A 22 year old woman presented to a district general hospital with an overdose of tramadol and paroxetine. She was morbidly obese with a body mass index of 51. She had been admitted to the hospital's accident and emergency department several times previously for deliberate self harm and had required surgery to remove foreign bodies from her abdominal wall. After treatment for the overdose, the patient was discharged with community psychiatric follow-up. Roughly 30 minutes after discharge, while still in the hospital grounds, she poured lighter fluid over her head and neck and set herself alight. Spotted by nearby paramedics, she was readmitted with 15% mixed depth burns to the head and neck. As the clinical signs suggested a serious airway injury, she was intubated, admitted to the intensive care unit for an overnight stay, and transferred to a regional burns centre the following day.

On admission to the burns unit, she had the burnt skin removed and a surgical tracheostomy. It was during the scrubbing and excision of the burnt skin that the theatre team spotted a tattoo under the dressings (figure 1). In a prominent place on her chest, the tattoo read "DNR, do not resuscitate." No advance directive was found in the patient's notes. This unexpected discovery triggered a debate among the team in the operating room. After discussing the possible options, the team proceeded to initiate further resuscitative treatment on the grounds of "best interests." The rest of the patient's stay in intensive care was uneventful and she was eventually discharged to a psychiatric care facility.

No medical ethicist was available at the time of the decision, but the theatre team contacted an ethicist (DKS) afterwards in search of a framework with which to analyse this and future cases and, to some extent, to validate their decision. What should the theatre team, suddenly faced with this ethical dilemma, have discussed?

Below, we use the four quadrants method to analyse the case and show how to put ethics into practice across a wide range of medical specialties.¹ The approach consists of four broad topics or quadrants: medical indications, patient preferences, quality of life, and contextual features.² The approach is entirely compatible with the widely used four principles of medical ethics (respect for autonomy, beneficence, non-maleficence, and justice).^{1,3}

Medical indications

The first step in any clinical ethics analysis should be the easiest for doctors. It consists of reviewing the medical situation, identifying the clinical problems and the treatment options, and determining how the patient can be benefitted medically with minimum harm. It is particularly important to establish the goals of the proposed treatment and the probabilities of success.

Although the patient in the above case had a difficult airway as a result of the burns, swelling, and a body mass index of 51, the medical indications were not in doubt. This was a young woman with reversible problems and a good prognosis. From a clinical perspective she required urgent resuscitative care including invasive monitoring, ventilation, fluid resuscitation, skin debridements, and enteral feeding. The goals of treatment were cure, restoration of function, and prolongation of life, and the probability of success was high.

Patient preferences

The second quadrant puts in practice the principle of respect for autonomy. It focuses on the wishes, or presumed wishes, of the patient. In North America and the United Kingdom a competent patient is legally entitled to refuse medical treatment, even if it will result in death. Before asking what the patient

wants, we need to establish if the patient is mentally capable of making an autonomous decision. If the patient is temporarily unconscious and urgent treatment is not necessary, it is advisable to wait until the patient regains consciousness and ask him or her directly about a proposed major intervention. It may be inconvenient for the staff, but such is the cost of taking the principle of respect for autonomy seriously.

Inconvenience aside, there are potential legal repercussions of failing to seek the patient's views. In the words of the former Master of the Rolls, Lord Donaldson: "It is trite law that in general a doctor is not entitled to treat a patient without the consent of someone who is authorised to give consent. If he does so, he will be liable in damages for trespass to the person and may be guilty of a criminal assault."⁴

If time is of the essence, we can look for evidence of past wishes from advance directives, the accounts of relatives and friends, or the patient's general practitioner. Many hospital teams overlook the possibility of contacting the general practitioner, who often has relevant information.

In this case, there was no advance decision, at least not in the formal sense. Although the instruction in the tattoo was clear, the validity was uncertain. Was the tattoo done several years ago during a bout of acute depression? Was it done as a joke or a dare? Or was it inscribed during a moment of lucidity? There was considerable uncertainty about how closely the tattoo represented her current, deeply held wishes. In other circumstances, the team could have sought clarification of the patient's views from her relatives or general practitioner, but here immediate treatment was necessary to prevent further deterioration of her condition.

Going to a shop to buy the lighter fluid and matches and inscribing a tattoo as an advance directive may suggest rational planning. The repeated attempts at self harm may also indicate a consistent belief, but equally these facts could reveal an abnormality of mind. A finding of mental abnormality does not mean that we should automatically disregard the patient's views, but it does call for greater caution in interpreting those views. Setting yourself alight in hospital grounds, in close proximity to paramedics and medical care, may suggest a cry for help rather than a desire to die.

So what are this patient's autonomous preferences? The answer must be that we do not know. The criminal standard of proof, "beyond reasonable doubt," is more appropriate in this context than the much lower civil standard of "on the balance of probabilities." A patient's life is at stake, and the risk of getting it wrong—of failing to resuscitate contrary to the patient's true wishes—is too high, the consequences too grave, to warrant the gamble.

Quality of life

The purpose of medicine is not merely to prolong life but to improve its quality. It is therefore essential to consider how a proposed intervention will affect the patient's quality of life. This is the task of the third quadrant. What physical, mental, and social deficits will the patient experience if the treatment works? Will the patient deem life to be desirable or will it be so grim that continued life will be a curse rather than a blessing? There is a strong subjective component to quality of life and again uncertainty reigns. We cannot know how our patient will react after treatment. Will she be grateful for receiving another chance at life or will she be devastated at what she may perceive as a gross infringement on her liberty and autonomy?

Our evaluation of the quality of life of another person is subject to bias. Our beliefs about life and death, our general disposition and outlook, and our experiences all colour our judgment. We can to some extent dilute the bias by being aware of it and talking to colleagues whose biases may differ from our own. The solution, of course, is to ask the person concerned about his or her quality of life, but that is not always possible.

Under this quadrant, our medical team must again conclude that the patient has good prospects of returning to a state similar to the one she was in before the episode. Although she was evidently unhappy at the time of the suicide attempt, we cannot predict how she will perceive her quality of life after treatment or how this perception will evolve with time. This episode may be the trigger for a changed and better outlook. The team must therefore err on the side of caution and assume that treatment is indicated on quality of life grounds or, at least, not contraindicated.

Contextual factors

This final quadrant considers legal, cultural, familial, religious, economic, and other factors not captured by the other three sections. What does the law require? In the United Kingdom, when there is an imminent risk of serious harm and in the absence of a legally binding advance decision, it is lawful to resuscitate without consent if it is in the best interests of the patient. If best interests are unclear—and time permits—the hospital legal team could be consulted. The tattooed advance directive was not legally binding because it was not signed and witnessed. It was not verified by the patient's statement that it should apply even if life was at risk. In light of her psychiatric history, there was also reason to doubt her competence when she had the tattoo.

This quadrant is less defined than the others, setting the problem in a wider context. In emergency situations, it would be inappropriate or impractical to discuss some of these macro issues, such as the ethics of allocating scarce resources to treat patients who repeatedly attempt suicide.

Conclusion

In the cold light of day, this case may seem straightforward. Yet, at the time, under pressure, and with the patient's apparent wishes so plainly and strikingly inscribed on her body, doubt lingered. It will not always be possible to address all the issues raised by the four quadrants at the bedside, but even when time is short it should be possible to examine the key elements. The approach, like all other methods of which we are aware, will not always yield a clear cut solution. The primary purposes are to provide a structured way of thinking about ethics in practice and to raise ethico-legal issues that may otherwise remain unexplored by clinicians acting in the heat of the moment.

In the present case, the positive clinical outlook, the reasonable uncertainty about the patient's true wishes, the potential for an improved quality of life in the future, and the clear legal position, strongly pointed in favour of resuscitation, despite the apparently contrary directions of the tattoo. Nevertheless, there is something troubling about the photograph of our patient unconscious on the operating table, with the tracheostomy and other external signs of aggressive resuscitation next to the tattoo's instructions (figure 1). Situations such as this, where the head and the heart—at least initially—pull in opposite directions (the head towards resuscitation, the heart towards respecting the patient's apparent wishes) and where clinicians may disagree over the right course of action, are a good reason to use a

structured method of analysis as a common starting point for discussion.

The use of a clear method is also consistent with the twin obligations to learn from experience by examining our decision making and to share the stories and lessons with colleagues so that they too can learn.

Postscript

The patient continued to be depressed after recovery. She did not complain or display any anger about the intervention; nor did she express any gratitude. Two weeks after discharge, she died suddenly. The postmortem examination was inconclusive.

We thank the parents of the patient for giving consent to publish details of the case. We also thank Raanan Gillon, Nneka Mokwunye, and Albert Jonsen for useful comments.

Contributors and sources: ISW is a plastic surgeon who was part of the burns unit treating the patient in the case. WAD is a plastic surgery consultant in charge of the treatment of the patient, and director of the Welsh burns centre. WAM is a consultant anaesthetist who was integral in the treatment of the patient. DKS is a medical ethicist who has worked

in hospitals doing clinical ethics. Each author contributed to the idea and content of the manuscript. ISW is the guarantor.

Competing interests: All authors have completed the ICJME unified disclosure form at www.icmje.org/coi_disclosure.pdf (available on request from the corresponding author) and declare: no financial support for the submitted work from anyone other than their employer; no financial relationships with commercial entities that might have an interest in the submitted work; and no non-financial interests that may be relevant to the submitted work.

Provenance and peer review: Not commissioned; externally peer reviewed.

Patient consent: The patient's family has given permission to publish the case.

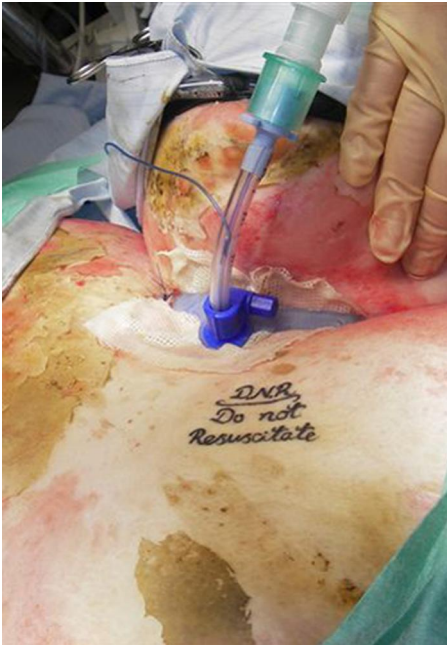
- 1 Jonsen A, Siegler M, Winslade W. Clinical ethics: a practical approach to ethical decisions in clinical medicine. Mc-Graw Hill, 2006.
- 2 Sokol D. The four quadrants approach to clinical ethics case analysis; an application and review. *J Med Ethics* 2008;34:513-6.
- 3 Beauchamp T, Childress J. Principles of biomedical ethics. Oxford University Press, 2009.
- 4 *Re R (A Minor)*. Wardship (consent to treatment). [1992] Fam 11.

Accepted: 10 August 2011

Cite this as: *BMJ* 2011;343:d5528

© BMJ Publishing Group Ltd 2011

Figure



"Do not resuscitate" tattoo on patient's chest